

Ingrown Toenail: A Result of Weight Bearing on Soft Tissue

CAPTAIN KERMIT Q. VANDENBOS, USAF, MC
COLONEL WARNER F. BOWERS, MC, USA

INGROWN TOENAIL is an important and frequent cause of loss of duty time in military patients. Because the pathologic physiology is not generally understood, there are many types of treatment advocated and the recurrence rate is high. The term "ingrown toenail" is unfortunate in that it incriminates the nail as the causative factor and is responsible for the fact that most operative and conservative treatments are directed toward the nail. It is our thesis that persons who develop this condition have an unusually wide area of tissue medial and lateral to the nail and that with weight bearing this tissue tends to bulge up around the nail. When such persons trim the nails in a curved or rounded fashion instead of straight across, further bulging of soft tissue is allowed, and as the nail grows out, pressure necrosis of soft tissue occurs. If our thesis that the fault lies not with the nail but with an excess of soft tissue is correct, treatment by removal of a segment of nail is not rational. It increases the relative amount of soft tissue and predisposes to recurrence, and at the same time inept attempts to remove some nail matrix lead to faulty regrowth of the nail. The logical conclusion is that soft tissue should be excised, so that with weight bearing there will be no tissue to bulge up around the nail. We are not discussing the thick, discolored, deformed nails seen in old people, nor trophic changes, fungus infections, and excessively curved nails which pinch the soft tissues of the toe. These are separate groups in which we usually simply avulse the nail by rolling it from its bed and then apply fungicides or whatever specific therapy is indicated.

The Tripler U.S. Army Hospital records of 99 patients admitted for ingrown toenails between December 1949 and September 1956 have been reviewed. Many forms of conservative and palliative surgical treatment were used, and although follow-up is impossible, we know from our current series that recurrence has been frequent.

From Tripler U.S. Army Hospital, APO 438, San Francisco, Calif. Dr. Vandenberg is now at U.S. Air Force Hospital, Langley Air Force Base, Va.

INGROWN TOENAIL

Hot soaks, cold soaks, parenteral and topical antibiotics, silver nitrate, and even cautery were used on the painful soft tissues of the toe in an attempt to reduce the inflammation. Painful wedging of cotton underneath the edge of the nail so as to relieve the pressure on the soft tissue was often combined with this (fig. 1a). Shaving the center or removing a central wedge of the nail was also used to relieve the pressure of the nail upon the soft tissues (fig. 1b). In some cases adhesive tape was applied tightly about the toe in an attempt to draw soft tissue away from the nail (fig. 1c). In other cases, the whole nail was rolled off under local anesthesia (fig. 1d), or perhaps a lateral portion of the nail was removed with a special hooked knife (fig. 1e). Removing the nail would relieve the patient's symptoms only temporarily and the condition would recur with the regrown nail. To reduce the amount of soft tissue on the lateral or medial aspect of the toe, a wedge of normal tissue was removed in a few cases (fig. 1f). The most common surgical treatment was excision of the lateral fourth or third of the nail together with the granulation tissue and some of the soft tissue of the toe (fig. 1g). Although many patients benefited from this procedure, many had recurrence of their disease when the nail regrew. In an attempt to stop regrowth of the lateral or medial portion of the removed nail, the base of that portion of the nail and of its bed was often excised sharply, curetted, or even treated with caustics, in some cases down to and including the periosteum of the bone. The common end result was the regrowth of a deformed, thick hooked nail that became as painful as the initial condition (fig. 1h).

Since September 1956 we have advocated a more physiologic and sounder surgical approach to the patient with the "ingrown toenail." Fifty-five patients, 12 of whom had both great toes involved, have been treated as described below.

Patients with a severe purulent infection of the soft tissue are treated with local saline soaks or wet dressings and bed rest for a few days until the inflammation has partially subsided. Antibiotics are not necessary and have not been used. Then, under general nitrous oxide and oxygen anesthesia, or under field or local procaine block anesthesia, the toe is cleansed with soap and water. A generous excision of all soft tissue on the involved side of the toe is performed, starting at the edge of the normal nail and leaving the nail intact (fig. 2a, b, c). The excision must be generous and adequate, often exposing a portion of the lateral aspect of the distal phalanx of the toe. The excision extends at least 0.5 cm behind the level of the base of the nail and is carried out completely to the end of the toe. Any

U. S. ARMED FORCES MEDICAL JOURNAL

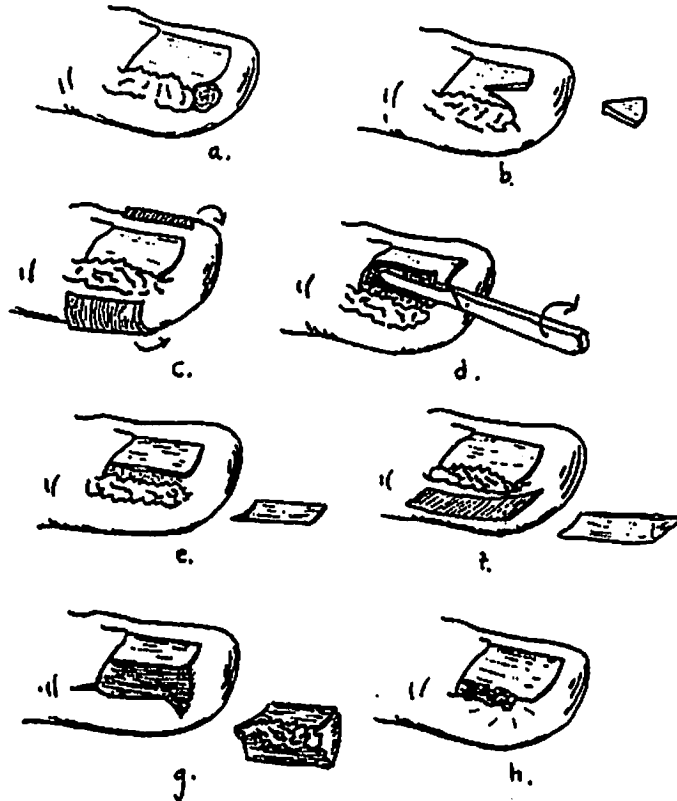


Figure 1. Methods of palliative treatment inviting recurrence of ingrown toenail. (a) Placing a cotton pledget beneath the corner of the nail until it has grown sufficiently long to be cut square across is suitable for early mild cases. (b) Excising a wedge of nail or shaving the nail thin in its central portion tends to make the nail curl, raising the edges from the tissues. (c) Adhesive strapping to pull soft tissue away from the nail. (d) Avulsing the nail by rolling it from its bed requires careful follow-up during the regrowing period. Some authors advocate rolling out the edge on the involved side only and then dropping the nail back to lie on the surface of the area of inflammation. (e) Removing a strip of nail and its matrix, based on the false premise that the nail is causative. (f) Removing a wedge of soft tissue. (g) Removing a strip of nail, matrix, and soft tissue, a more radical form of "c." (h) A regenerated crooked, thickened, deformed nail may be as symptomatic as the original condition.

INGROWN TOENAIL

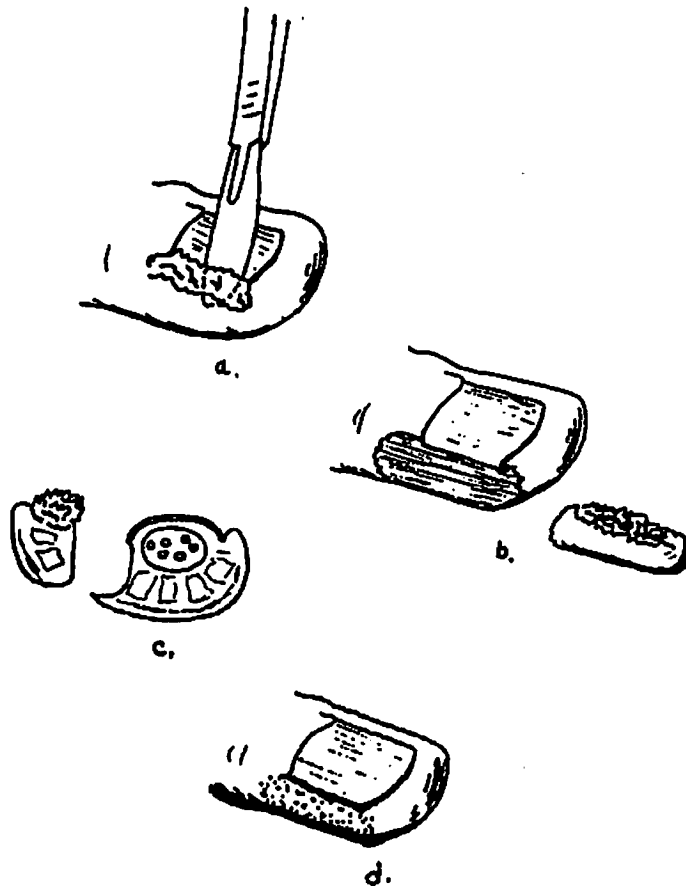


Figure 2. Recommended surgical treatment of ingrown toenail. (a and b) Soft tissue in the inflammatory area is excised generously to prevent impingement of nail on soft tissue. (c) Cross-sectional view, somewhat exaggerated in that the wound surface is more concave than usual. In a case such as this, the plantar skin could serve as a graft to part of the defect, either with a single stitch or by pressure from a dressing. Usually a flatter excision is desirable (see text). (d) Healing gives a painless surface which has not involved the plantar aspect, leaving no tissue to bulge up around the nail on weight bearing.

prominent bleeding vessels are clamped and tied with fine gut sutures. When the excision is done adequately, there is often a skin and soft tissue deficiency measuring 1.5 by 3 cm. This open wound is covered with fine mesh gauze and then bandaged. The patient soaks the bandage from the raw area 24 to 48 hours postoperatively, and re-

U. S. ARMED FORCES MEDICAL JOURNAL

peats this soaking 3 to 4 times a day as the wound gradually epithelializes from the periphery inward. Daily bandaging is not necessary. In most cases the patient is able to wear loose-fitting shoes within 2 to 3 weeks. The end result is a healed toe with little or no lateral or medial soft tissue and a normal nail (fig. 2d).

In an attempt to shorten the convalescent period, in a few patients a very short flap of skin was left on the inferior aspect of the excised soft tissue area, and this flap was brought up and sutured down over the wound with one suture near the edge of the nail. The thin skin flap became necrotic and sloughed on a few occasions, and in a few other cases collections of purulent exudate under the flap occurred, delaying the eventual healing process. This refinement of the surgical procedure did not shorten the convalescent period and has since been abandoned.

A complication that required re-hospitalization and additional treatment occurred in only 1 of the 55 patients treated. To the best of our knowledge, there have been no recurrences using our method.

CASE REPORT

A 19-year-old Army private had been unable to perform infantry duty for 8 months because of severe unguis incarnatus of the right great toe. Surgical

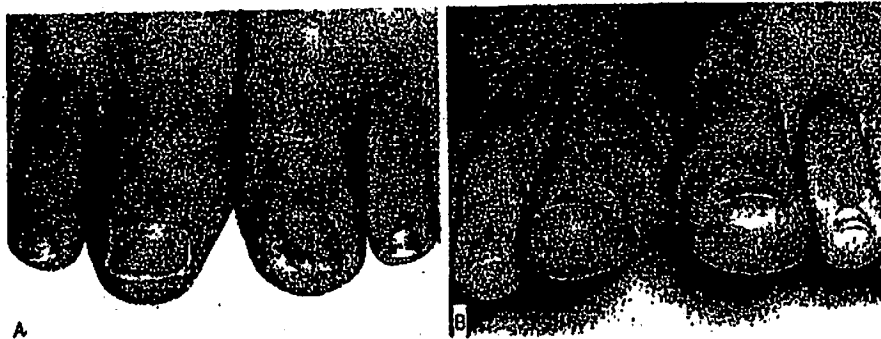

Figure 3. Bilateral ingrown toenails in 19-year-old soldier. (a) Dorsal view. Contoured right toe with no excess of soft tissue, 10 months following recommended surgical treatment of ingrown nail. Left ingrown nail has large area of soft tissue both medial and lateral to the nail; with weight bearing, this nail would become buried in soft tissue. (b) End-on view, showing more dramatically the lack of soft tissue bulge on right as compared with the overriding of soft tissue on left. Note that nails actually are the same width, but the left appears only about half as wide as the right because of the soft tissue bulge.

INGROWN TOENAIL

removal of the medial and lateral soft tissues of the toe was accomplished in September 1957. The patient was returned to duty in 3 weeks. He was re-hospitalized in April 1958, at which time there was a tender, raised keratotic growth 4 mm in height and 1 cm in diameter covering a portion of the medial aspect of the re-epithelialized toe. The keratotic area was excised and the wound was allowed to re-epithelialize. Cultures and microscopic examinations of the removed tissue were unremarkable. The patient returned to duty after an additional 32 days of hospitalization. In January 1959 the patient was admitted for excision of the soft tissue of the symptomatic left great toe. The right great toe had been asymptomatic (fig. 3).

There have been no cases of osteomyelitis of the distal phalanx.

SUMMARY AND CONCLUSIONS

Ingrown toenail is a phenomenon secondary to weight bearing in persons with excessive soft tissue medial or lateral to the nail border. There is no change in the nail itself (excluding fungus infection and other entities not germane to this discussion), and excision of a strip of nail simply increase the relative amount of soft tissue, predisposing to recurrence and nail deformity. Based on this thesis, logical surgical treatment would be excision of soft tissue to remove all excess tissue into which the nail could be pushed on weight bearing. Such a method has been used with excellent results in 55 patients since September 1956 without known recurrence.

REFERENCE

1. JANSEY, F.: Etiologic therapy of ingrowing toenail. *Quart. Bull. Northwestern Univ. M. School* 29: 358-362, Winter, 1955.

SICK CALL 150 YEARS AGO

The life of the soldier, like every other life of irregular exertion and hardship, predisposes to disease while, from the nature of the service, the treatment of military diseases differs from common practice, and requires peculiar experience, both in preventing the attack and also rendering their cure speedy and complete. Having it in mind that military practice requires bold and energetic measures; and that the soldier's absence from duty on the day of actual service is perhaps an irreparable loss to the country . . . hence the necessity of a medical officer possessing superior professional knowledge to others, much decision, and a good deal of acquired experience.—From a letter written in 1808 by Dr. Nisbet to His Royal Highness, The Duke of York: Quoted by Surgeon-Major A. A. Gore in *THE STORY OF OUR SERVICES UNDER THE CROWN*, London, 1879. Reprinted from *Journal of the Royal Army Medical Corps*, October 1958.